

Comparison of Diagnostic Accuracy of Indirect Digital Radiography and Paper Print Images in Vertical Root Fracture (*In vitro*)

Sanaz Sharifi Shooshtari, Mashid Razavy, Mehraban Mohamadian, Lida Naderi*

Department of Oral and Maxillofacial Radiology, Faculty of Dentistry, Ahvaz Jundishapur University of Medical Sciences, Ahvaz, Iran

ABSTRACT

Background and Aim: The development of dental treatments and the long-term maintenance of teeth increased the incidence of complications such as root fractures. Failure to detect root fractures may lead to progressive bone loss and unnecessary treatments. Therefore, an early diagnosis of this complication is important for both the patient and dentist. The role of radiographic examinations in the detection of such lesions is remarkable. The current study aimed at determining the diagnostic accuracy of digital radiography images printed on paper in vertical root fractures and comparing its efficacy with indirect digital radiography.

Materials and Methods: The current *in vitro* study was conducted on 40 extracted human premolars that were fixed by using wax in the sheep mandibular bone. Imaging of the mounted teeth was performed horizontally at 0° and 15° using an X-ray machine (XGenus, De Götzen SRL, Varese, Italy) on the photostimulable storage phosphor (PSP) image plate. Then the teeth were extracted from the bony socket of the mandible. After creating a vertical root fracture and fastening the two-piece, the teeth were again fixed with wax in the mandible and indirect digital images were taken under the conditions similar to those of the initial ones. All images were processed by Digora Optime (Soredex, Orion Corporation, Helsinki, Finland) and then transferred to Scanora 5.0 (Soredex Corp, Helsinki, Finland). The images were inverted into the desired size using Scanora, and then all were printed on a silk paper (Fujifilm, São Paulo, Brazil) using an hp color laserjet 1600 printer, 2400 dpi. The images displayed on monitors and printed on papers were separately assessed by two radiologists and the data were analyzed by statistical tests, proportions, and Cochran formula. The agreement between the observers was determined by Kappa index ($\alpha=0.05$).

Results: The sensitivity, specificity, positive predictive value (PPV), and negative predictive value (NPV) of vertical root fracture detection in images printed on paper were not significantly different from those of indirect digital radiographic images ($P>0.05$).

Conclusion: There were no significant differences between the diagnostic accuracy of indirect digital images (PSP) displayed on monitors and paper printed images in the detection of vertical root fractures. Therefore, in order to detect the vertical root fractures, use of paper printed images can be considered as a complementary method, but not a specific diagnostic method.

Key words: Vertical tooth fracture, Digital radiography, Paper image

HOW TO CITE THIS ARTICLE: Sanaz Sharifi Shooshtari, Mashid Razavy, Mehraban Mohamadian, Lida Naderi*, Comparison of diagnostic accuracy of indirect digital radiography and paper print images in vertical root fracture (*in vitro*), J Res Med Dent Sci, 2018, 6 (5):156-160

Corresponding author: Lida Naderi
e-mail ✉: lida.naderi@iran.ir
Received: 18/08/2018
Accepted: 15/09/2018

INTRODUCTION

Root fractures may involve dentin, cement, and pulp, and have relatively low prevalence among dental traumas, and constitute 4%-6% of all injuries to deciduous teeth and 0.5%-7% of permanent teeth traumas. The root fracture mechanism is usually a frontal blow that creates two pressure regions in the labial and lingual

parts, and as a result, a shear force is formed at the level connecting these two regions that causes the fracture at this level [1]. Vertical root fractures often involve teeth with complicated repairs; teeth underwent root canal treatments, or teeth with posts. Vertical fractures are seen at the buccal-lingual surfaces and may be an incomplete fracture. There are two etiologies for such fractures: 1) Bonding and cementing a post into the root canal; 2) The forces caused by compression during filling the root canal [2,3]. Detection of such fractures largely depends on radiographic examination and use of new methods in this area seems essential [4,5]. The adverse effects of inadequate processing on

the quality of radiography films and the difficulties in preserving the processing solutions at high quality are the common problems in dentistry [4]. The emergence of digital imaging technology evolved radiography. There is no reappearance and processing steps in the digital radiography system; the receiver transfers visual information directly (such as the CCD) or after processing in an indirect digital system (such as the PSP) into the computer, and finally the image is displayed on monitor; the ability to change the image quality-i.e., contrast and density-as well as its storage and transfer into other centers are also provided by this system [6].

The digital imaging is employed in dentistry since the last decade and its use by dentists is increasing [7]. The use of indirect digital radiography in diagnostic and therapeutic practices is increasing and it has the wide range of developments in dentistry. On the one hand, lack of radiographic films and domestic productions as well as its high cost led to improvement in the printing industry in recent decades and innovation high-quality paper-based printers and papers used in photography. Some studies compared paper printed images with images displayed on monitor. No study has compared diagnostic accuracy of vertical root fracture in paper printed images with same images displayed on monitor. The current study, by benefitting from these techniques, aimed at comparing the quality of images printed on fine quality papers with indirect digital radiography (PSP) imaged displayed on monitors in order to detect vertical root fractures.

MATERIALS AND METHOD

The current *in vitro* study was conducted on 40 single-rooted human premolar teeth that were recently drawn. The teeth were fixed with wax in the socket of sheep's alveolar bone. To simulate soft tissue, three layers of wax were applied on sheep mandible. The alveolar bone was vertically fixed on the base by putty. An indirect digital radiography plate (PSP) was used as the receiver that was placed at a constant distance of 10 cm from the radiographic tube. The alveolar bone was placed between the radiation source and 5 cm away from the receiver. Indirect digital images (PSP) of each tooth were prepared separately by the periapical imaging apparatus (XGenus, De Götzen SRL, Varese, Italy) (Figure 1).



Figure 1: Periapical image of premolar tooth by parallel procedure in separate holes drilled in mandibular bone of sheep

Exposure conditions were 70 kvp and 8 mA at 0.32 second. The teeth were then removed from the jaws and fixed in the clamp and by applying the mechanical force using hammer and nail, the vertical fracture was created and two broken pieces were fastened together with glue and the teeth were restored to the bone sockets and radiographs were prepared again in the same manner and then, were stored (Figure 2). The images were coded as with and without fracture. All images were processed by Digora Optime (Soredex, Orion Corporation, Helsinki, Finland) and then transferred into Scanora 5.0 (Soredex Corp, Helsinki, Finland).

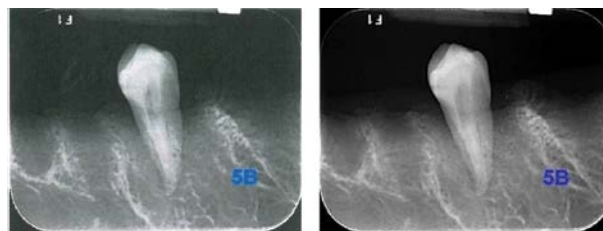


Figure 2: A radiography of specimen after vertical root fracture in zero degree. A) Paper print image, B) Image displayed on monitor

All the images, with or without fracture, were printed using a hp color laserjet 1600 printer, 2400 dpi, on a silk paper (Fujifilm, São Paulo, Brazil). The 1360 × 768 pixel images sized 496 × 391 × 202 mm were evaluated on a LG monitor by two radiologists with at least two years experiences in digital radiography that were blind to samples codifications. Paper printed images were also separately examined by the same radiologists. Data were analyzed with SPSS version 22 (SPSS Inc., Chicago, IL), Cochran, proportions, and Kappa tests. The significance level was 0.05.

RESULTS

The samples included 40 premolar teeth fixed in the sheep hemi-mandible. All the samples underwent indirect digital radiography horizontally at 0° and 15°. At this stage, 80 images were obtained. Indirect digital radiography was performed after the creation of vertical fracture under the same conditions as the initial digital imaging was performed. The number of images taken at this stage was 80. A total of 160 radiographic images were obtained. Images were stored in Scanora® (Version 4.3.1). The entire images displayed on monitor and printed on paper were evaluated by two observers to determine the existence of vertical fractures. All the images, with and without fracture, were printed on a silk paper using a hp color laserjet 1600 printer, 2400 dpi. The evaluation results of the two observers are shown in Table 1.

The two observers' evaluation results were compared. The standard Kappa index for the first and second observers was 22% and 28%, respectively. Due to higher accuracy of the second observer, his results were used

Table 1: The evaluation results of two observers

Accuracy	NPV	PPV	Specificity	Sensitivity	All	Standard			
						Negative	Positive		
0.61	0.59	0.65	0.74	0.49	120	42	78	Positive	Observer1
					200	118	82	Negative	
					320	160	160	All	
0.64	0.63	0.64	0.65	0.63	156	56	100	Positive	Observer2
					164	104	60	Negative	
					320	160	160	All	

to compare the diagnostic indices in different situations (angles and methods). In the current study, four diagnostic indicators including sensitivity, specificity, PPV, and NPV were used.

The highest sensitivity was observed at 0° and the monitor method (0.70) and the lowest sensitivity belonged to 0° and the paper print method (0.5). The highest specificity was observed at 0° and the monitor displayed method (0.75) and the lowest sensitivity was related to 15° (0.6). The highest PPV was obtained at 0° and the monitor method (0.74). The lowest PPV reported from 0° and paper print method (0.59).

NPV was in the lowest at 0° and the paper print method (0.57). There were no significant difference between the monitor displayed and paper printed images in the detection of vertical root fracture evaluation by indirect digital radiography ($P < 0.05$) (Table 2).

Table 2: The significance level of statistical indices in two techniques "monitor displayed" and "paper print" (Proportions's test was used)

P-value	Monitor	Paper print	Angle	Indicators
0.062	0.7	0.5	0	sensitivity
1	0.65	0.65	15	
0.326	0.75	0.65	0	Specificity
1	0.6	0.6	15	
0.179	0.74	0.59	0	PPV
1	0.62	0.62	15	
0.14	0.71	0.57	0	NPV
1	0.63	0.63	15	

In general, there were no significant difference between the indices in both monitor displayed and paper printed methods at 15°. In all the indices at 0°, the monitor displayed method had a better performance than the paper printed method. However, there were no significant differences between the methods and angles with 5% standard error, but the performance of the monitor displayed method at 0° was far better than other situations.

DISCUSSION

Radiographic diagnosis of vertical root fracture is one of the most important concerns of today dentistry and is one of the most problematic cases in dental care, which requires high accuracy. Vertical root fracture does not

always causes a considerable discomfort to patient, but in long term can cause progressive destruction in periodontal ligament, bone, and surrounding tissue [8]. Therefore, if root fractures are not successfully diagnosed, the restoration and future treatment plan may be problematic [9]. Accordingly, an accurate imaging method for the early detection of such conditions has always been a concern for dentists.

Radiography is a simple, low-cost, and available method that can be used as an adjuvant diagnostic technique in the detection of vertical root fractures. Digital radiography also provides conditions for better diagnosis and treatment for the clinicians due to capabilities such as contrast and density enhancement, etc., [10]. Accordingly, the use of both intra- and extra-oral radiography is increasing, so the evaluation of their diagnostic values seems necessary [11]. On the other hand, the possibility of providing a paper print of a radiographic image is one of the other benefits of these imaging techniques, which can be used in some cases, such as the impossibility of displaying the images on monitor, and patient or other treatment groups' request. One of the remarkable advantages of the paper print method is its sensitivity and specificity in comparison with other methods, such as monitor display and radiographic stereotype. Due to the limited researches conducted on the features of digital radiography images printed on paper, the current study investigated the specificity and sensitivity of indirect digital radiography (PSP) images horizontally at 0° and 15° displayed on monitor and printed on paper horizontally at 0° and 15° based on radiologists' assessments to detect vertical root fractures. The findings of the current study showed no significant differences between images provided by paper print and monitor display methods at 0° and 15° in terms of sensitivity, specificity, PPV, and NPV. However, all the indices were higher in the monitor display method. There was also no significant difference in the studied indices between 0° and 15° in the monitor display method, although at 0° all the indices were higher. There was no significant difference in the studied indices between 0° and 15° in the paper print method, although the indices were higher at 15°.

Various studies directly or indirectly investigated the quality of digital radiography images printed on paper and reported similar or contradictory results compared with those of the present study. Sharifi et al. in Iran compared the diagnostic accuracy of stereotypes and

paper printed images by indirect digital radiography (PSP) to detect periapical lesions. Their results showed no significant differences between the specificity and sensitivity of the methods in different image sizes to detect periapical lesions [12]. Based on the results of the current study, radiographic stereotypes can be replaced with paper prints in clinical trials. However, the radiographic stereotypes were not used in the current study and the studied lesion was also different (periapical lesions vs. vertical root fractures), but due to the insignificant difference between the paper printed images and radiographic stereotypes in their study and acceptability of paper printed images, it can be concluded that their results are consistent with those of the current study. Mehrzadeh *et al.* conducted a study in Iran on the diagnostic accuracy of direct digital radiography (CCD) for images displayed on monitor and printed on paper, and compared the results with those of the histological method in the detection of proximal dentinal caries. They reported no significant differences between the methods based on PPV and NPV. Lower diagnostic accuracy was observed in the paper printed method compared with the direct digital radiography, although the difference was insignificant ($P < 0.3$) [13]. Their results showed that the diagnostic accuracy of two monitor displayed and paper printed methods by direct digital radiography in the detection of dental caries was similar, and the diagnostic accuracy of paper printed method was approximately similar to that of direct digital radiography and this method can be used as an instrument to transfer direct digital radiographic images. Nevertheless, they used digital direct radiography, while in the current study indirect digital method was used and the studied lesions were also different, the findings of their study were similar to those of the current study.

Both studies suggested the use of paper printed images for the detection of dental problems. In a study in Iran, Shams *et al.* compared a number of proximal caries illustrated on stereotypes, paper printed images, and monitors in intraoral indirect digital radiography. The mean number of caries detected on stereotypes was greater than that of the paper printed images, followed by those of the monitor displayed method. The results of Wilcoxon test showed no significant difference between the two methods of paper print and monitor display ($p > 0.05$), but the difference between the stereotype method and two methods of paper print and monitor display was significant ($p < 0.001$) [14]. These results were similar to those of the current study, since in our study there were no significant differences between the sensitivity and specificity of the paper print and monitor display methods in the detection of lesions. Schulze *et al.* in Germany, in a study compared dental radiographs, printed on glossy papers using thermal and inkjet printers, and direct digital radiography (CCD) imaged displayed on monitors in the detection of typical dental lesions (enlargement of the periodontal ligament, interproximal caries, apical lesions, marginal bone loss) and showed that the diagnostic accuracy of the glossy

paper printed images were similar to that of monitor displayed images with a confidence interval of 95%; no significant difference was found in the diagnostic accuracy between the paper printed and monitor displayed images. In general, their findings showed that dental radiography can be evaluated on glossy paper prints and there is no difference between these images and the original digital samples in terms of diagnostic accuracy [11]. The findings of their current study were consistent with those of our study. In a study by Kühl *et al.* [15], the diagnostic accuracy of paper prints, radiography films, and monitor displayed images were compared in the detection of periapical lesions. The results showed no statistically significant difference between the sensitivity of the paper printed and monitor displayed images in detection of the lesions, but there was a significant difference between the sensitivity of these two methods and that of radiographic stereotypes ($p < 0.001$). The results of their study were consistent with those of the current study in terms of insignificant differences between the specificity and sensitivity of paper printed and monitor displayed images; although different lesions and different digital radiography methods (direct vs. indirect) were used, both studies concluded the efficacy of paper print method.

Otis *et al.* [16] compared the diagnostic accuracy of simple intraoral radiography and glossy paper printed images (Norderstedt, Germany, NY) in detecting proximal caries using bitewing radiography technique. They reported no significant difference between the diagnostic accuracy of paper printed images and that of the stereotype radiographs, which is in agreement with the results of the present study. Despite the differences in the employed radiography technique and the type of paper, similar results confirmed the high capability of paper print method in reflecting details.

Liang *et al.* [17] studied the quality of paper printed and laser printed images in the detection of single-clustered microcalcification in digital mammography and concluded that the quality of laser printed images was much higher than that of paper prints that is inconsistent with the results of the present study. The difference can be attributed to different studied tissue.

In a study by Gijbels *et al.* in the Netherlands, the diagnostic accuracy of three different methods as direct thermal printing, monitor displaying, and inkjet printing on a variety of papers in the detection of dental caries were compared. The results showed significant differences among the studied methods in terms of the detection of caries. The direct thermal printed images had the highest quality and the inkjet printer ones had the lowest quality [18]. Their findings were inconsistent with those of the current study. In our study, there was no significant difference between sensitivity and specificity of the studied methods, while in the study by Gijbels *et al.* the differences were statistically significant. Differences in the results of the two studies can be attributed to

their different research method. It is noteworthy that in the past decades much progress has been made in the printing industry, which may change the result of the study by Gijbels et al. [18].

Findings of the most previously performed studies were very consistent with those of the current study, and in most cases the use of paper prints was accepted.

CONCLUSION

The diagnostic accuracy of indirect digital images (PSPs) on paper-based monitors is not significantly different in determining the vertical root fracture. Therefore, in order to detect the vertical fracture of the root of the printed paper, images can be considered as complementary methods, not monopolistic diagnostic methods.

REFERENCES

- Borum MK, Andreasen JO. Therapeutic and economic implications of traumatic dental injuries in Denmark: An estimate based on 7549 patients treated at a major trauma centre. *Int J Paediatr Dent* 2001; 11:249-58.
- Erdemir A, Ungor M, Erdemir EO. Orthodontic movement of a horizontally fractured tooth: A case report. *Dent Traumatol* 2005; 21:160-64.
- White SC, Pharoah MJ. *White and Pharoah's Oral Radiology E-Book: Principles and Interpretation*. Elsevier Health Sciences 2018.
- Andreasen JO, Andreasen FM, Andersson L. *Textbook and color atlas of traumatic injuries to the teeth*. Oxford: Blackwell Munksgaard 1993.
- Wang P, Yan XB, Lui DG, et al. Detection of dental root fractures by using cone-beam computed tomography. *Dentomaxillofac Radiol* 2011; 40:290-8.
- Cohen S, Burns RC, Walton R, et al. Pathways of the Pulp (1). *Learning* 1998; 30:10.
- Wenzel A, Møystad A. Experience of Norwegian general dental practitioners with solid state and storage phosphor detectors. *Dentomaxillofac Radiol* 2001; 30:203-8.
- Lustig JP, Tamse A, Fuss Z. Pattern of bone resorption in vertically fractured, endodontically treated teeth. *Oral Surg Oral Med Oral Pathol Oral Radiol Endod* 2000; 90:224-7.
- Bornstein MM, Wölner-Hanssen AB, Sendi P, et al. Comparison of intraoral radiography and limited cone beam computed tomography for the assessment of root-fractured permanent teeth. *Dent Traumatol* 2009; 25:571-7.
- Sakhdari S, Mehralizadeh S, Dadresanfar B, et al. Accuracy of reverse contrast option of digital radiography in detection of horizontal root fracture (*In vitro*). *J Res Dental Sci* 2011; 8:68-74.
- Schulze RK, Schulze D, Voss K, et al. Quality of individually calibrated customary printers for assessment of typical dental diagnoses on glossy paper prints: A multicenter pilot study. *Oral Surg Oral Med Oral Pathol Oral Radiol Endod* 2008; 106:578-86.
- Sharifi Shooshtari S, Niroomand N, Kazemnezhad M, et al. Comparison of diagnostic accuracy of indirect digital radiography and paper print in periapical lesion. *Jundishapur Scienti Med J* 2015; 14.
- Mehralizadeh S, Sadri D, Khalifeh S. Evaluation of intra oral digital radiography on paper print in proximal dentin caries detection. *J Res Dental Sci* 2009; 6:25-33.
- Shams N, Bayati S, Heidari S, et al. Comparison of numbers of detected caries proximal surfaces in bitewing radiographs printed *via* laserjet paper printer, drypix prima film printer and observation in monitor. *Jundishapur Scienti Med J* 2014.
- Kühl S, Krummenauer F, Dagassan-Berndt D, et al. Ink-jet printout of radiographs on transparent film and glossy paper *versus* monitor display: An ROC analysis. *Clin Oral Investig* 2011; 15:351-6.
- Otis LL, Sherman RG. Assessing the accuracy of caries diagnosis *via* radiograph: Film *versus* print. *J Am Dent Assoc* 2005; 136:323-30.
- Liang Z, Du X, Guo X, et al. Comparison of dry laser printer *versus* paper printer in full-field digital mammography. *Acta Radiol* 2010; 51:235-9.
- Gijbels F, Sanderink G, Pauwels H, et al. Subjective image quality of digital panoramic radiographs displayed on monitor and printed on various hardcopy media. *Clin Oral Investig* 2004; 8:25-9.